

# Retinal Pigment Epithelial Tear Developing in a Patient with Outer Retinal Tubulations: Pathogenic Association or Coincidence?

KONSTANTINOS T TSAOUSIS<sup>1</sup>, THEO EMPESLIDIS<sup>2</sup>

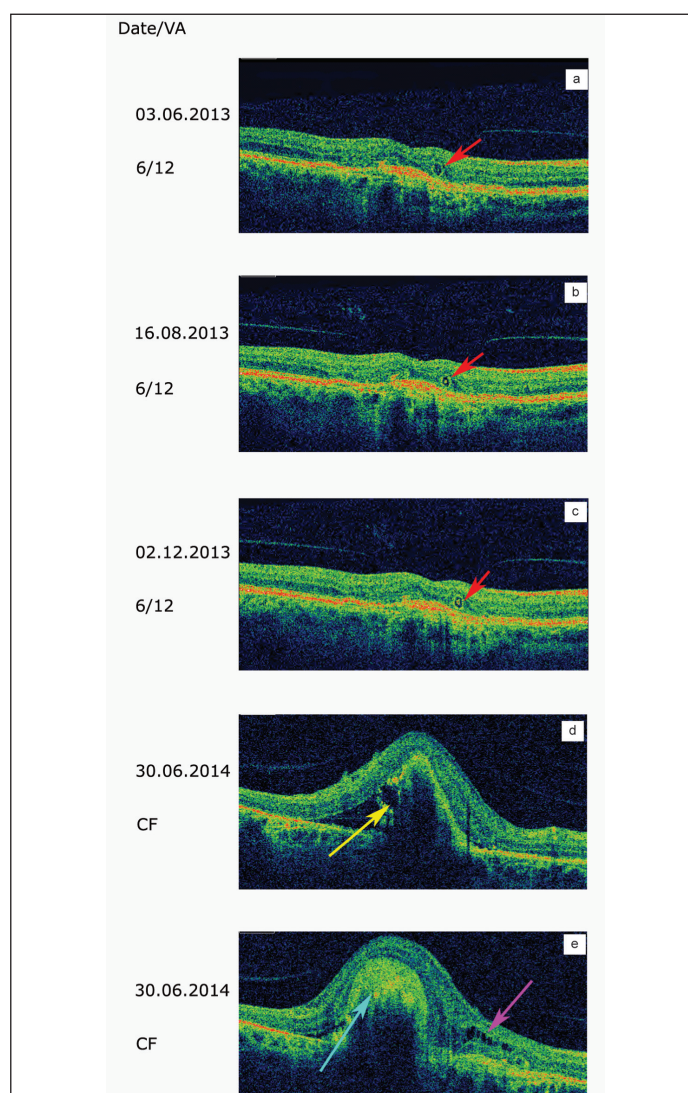
**Keywords:** spectral-domain optical coherence tomography; age-related macular degeneration, retinal anatomy

Outer Retinal Tubulations (ORTs) first described by Zweifel and colleagues [1], can be detected by Spectral Domain Optical Coherence Tomography (SD-OCT). They consist of round or ovoid structures with hyper-reflective borders and cavities which, in comparison, are hyporeflective. They were initially described in Age-related Macular Degeneration (AMD) but have since been reported in other conditions, including Bietti crystalline dystrophy and chronic central serous chorioretinopathy [2,3].

Zweifel proposed that they result from rearrangement of degenerate photoreceptors as a result of a loss of the interdigitation of the outer segments of the Retinal Pigment Epithelium (RPE) or as a consequence of the RPE degeneration itself [1]. Although their exact origin remains unclear, they are specific for the exudative form of AMD and may be a useful indicator of the stage of the disease and its severity. They are considered to be a negative prognostic factor, as their presence is associated with poorer visual outcomes.

We present the case of an 81-year-old female treated for wet AMD with three intravitreal injections of bevacizumab and six intravitreal injections of ranibizumab into her right eye. The last injection was in January 2012. She has subsequently been regularly followed up by the Medical Retina Service at the Leicester Royal Infirmary. Her best-corrected distance visual acuity was consistently 6/12, with no evidence of exudative activity while examination of her left eye was unremarkable and visual acuity was 6/9. However, ORTs were consistently evident on SD-OCT [Table/Fig-1a-c]. In addition, there was evidence of impaired integrity of the RPE. When seen last in June of 2014, she was found to have significantly decreased visual acuity in her right eye (counting figures at 0,5 meter) while she reported that she has not realized the vision loss and for that reason she did not present immediately for an eye test. Fundoscopy revealed a grade 4 retinal pigment epithelial tear, confirmed by SD-OCT [Table/Fig-1d,e]. She was informed of a lack of effective treatment for the specific grade of a retinal tear (extensive and central) and it was decided not to proceed to any intervention [4]. Visual acuity of the fellow eye was still 6/9 without any significant findings.

ORTs have been of interest to both clinicians and scientists. They are not detected by time domain OCT, but are usefully detected by SD-OCT. When first described, it was unclear which cells or tissues of the retina are principally involved in their formation. Schaal and colleagues recently published an important study correlating SD-OCT and histological findings and proposed classification into five categories [5]. Their study has been pivotal in helping to understand the nature of ORTs, although the precise role of the RPE remains uncertain. In our patient, it was clear that, despite she had satisfactory visual acuity but her RPE was significantly damaged



**[Table/Fig-1a-e]:** Photographic images obtained during the last year of follow up. a-c: ORTs are evident in SD-OCT images (red arrows). d: A giant retinal epithelial tear developed acutely and affected all of the central fovea (yellow arrow). e: Fibrotic tissue is present in the tear (light blue arrow). There are also cystic spaces with intraretinal fluid (pink arrow).

as a consequence of AMD. The relatively short period of 6 months between appointments was sufficient time for the development of a giant retinal epithelial tear, with consequent impairment of her central vision. Reactivation of wet AMD, particularly if there are RPE detachments, is often sufficient for a RPE tear to develop. However, our patient had no pre-existing detachments and had been clinically and anatomically stable for more than 2 years.

Our observation provides evidence for a link between ORTs and the integrity of the RPE. Furthermore, in patients with AMD, complications such as retinal pigment epithelium tears are more likely to occur in those with ORTs. Evidently, further studies are required to explain this linkage.

**Conflict of Interest Statement:** The authors report no conflict of interest. The authors alone are responsible for the content and writing of the paper.

**Consent:** Informed consent for the research was obtained from the patient described that the case could be used as the basis for this manuscript.

## ACKNOWLEDGMENTS

Dr. Tsaousis received a scholarship (2015) from the Hellenic Society of Intraocular Implants and Refractive Surgery for postgraduate training.

The Leicester Retina Service succeeded the national award of 'Clinical service of the year' for the year 2013.

## REFERENCES

- [1] Zweifel SA, Engelbert M, Laud K, Margolis R, Spaide RF, Freund KB. Outer retinal tubulation: a novel optical coherence tomography finding. *Arch Ophthalmol.* 2009; 127:1596-602.
- [2] Saatci AO, Doruk HC, Yaman A, Oner FH. Spectral domain optical coherence tomographic findings of bietti crystalline dystrophy. *J Ophthalmol.* 2014;2014:739271.
- [3] Gallego-Pinazo R, Marsiglia M, Mrejen S, Yannuzzi LA. Outer retinal tubulations in chronic central serous chorioretinopathy. *Graefes Arch Clin Exp Ophthalmol.* 2013;251:1655-56.
- [4] Empeslidis T, Vardarinos A, Konidaris V, et al. Incidence of retinal pigment epithelial tears and associated risk factors after treatment of age-related macular degeneration with intravitreal Anti-VEGF Injections. *Open Ophthalmol J.* 2014;8:101-04.
- [5] Schaal KB, Freund KB, Litts KM, Zhang Y, Messinger JD, Curcio CA. Outer retinal tubulation in advanced age-related macular degeneration: optical coherence tomographic findings correspond to histology. *Retina.* 2015;35:1339-50.

### PARTICULARS OF CONTRIBUTORS:

1. Consultant, Department of Ophthalmology, Leicester Royal Infirmary, Leicester, UK.
2. Consultant, Department of Ophthalmology, Leicester Royal Infirmary, Leicester, UK.

### NAME, ADDRESS, E-MAIL ID OF THE CORRESPONDING AUTHOR:

Dr. Konstantinos T Tsaousis,  
Consultant, Department of Ophthalmology, Medical Retina, Leicester Royal Infirmary,  
Infirmary Square, Leicester, LE1 5WW, UK.  
E-mail: konstantinos.tsaousis@gmail.com

**FINANCIAL OR OTHER COMPETING INTERESTS:** None.

Date of Submission: **May 15, 2016**  
Date of Peer Review: **Jun 08, 2016**  
Date of Acceptance: **Jun 16, 2016**  
Date of Publishing: **Aug 01, 2016**